



# EB-D fibronectin expression in squamous cell carcinoma of the head and neck

Paulette Mhawech<sup>a,\*</sup>, Pavel Dulguerov<sup>b</sup>, Mounia Assaly<sup>a</sup>,  
Carmen Ares<sup>c</sup>, Abdelkarim S. Allal<sup>c</sup>

<sup>a</sup> Department of Pathology, Geneva University Hospital, CMU Michel-Servet 1, Geneva 1211, Switzerland

<sup>b</sup> Division of Head and Neck Surgery, Geneva University Hospital, CMU Michel-Servet 1, Geneva 1211, Switzerland

<sup>c</sup> Division of Radiation Oncology, Geneva University Hospital, CMU Michel-Servet 1, Geneva 1211, Switzerland

Received 6 May 2004; accepted 12 July 2004

## KEYWORDS

ED-B fibronectin  
expression;  
Head and neck  
squamous cell  
carcinoma;  
Immunohistochemistry;  
Prognostic value

**Summary** ED-B fibronectin (ED-B FN), a glycoprotein involved in cell adhesion and migration, is expressed in fetal and neoplastic tissues and absent in their normal counterparts. The aim of this study is to evaluate the expression of this glycoprotein in relation to the histological and clinical data and to determine whether it has a prognostic value in patients with head and neck squamous cell carcinoma (HNSCC). Ninety-five cases were assessed for ED-B FN expression using immunohistochemistry. Positive ED-B FN expression was significantly associated with tumor grade ( $p = 0.06$ ) and primary tumor site ( $p = 0.02$ ). The larynx was the tumor site associated with the least ED-B FN expression. In univariate analysis, there was no association with disease-free survival ( $p = 0.48$ ), but the mean time to progression was clearly shorter in tumors with positive ED-B FN expression than in those with negative expression (6 vs. 11 months). Patients having tumors expressing the ED-B FN had a trend to a significant lower overall survival in the multivariate analysis ( $p = 0.06$ ). Our study showed that ED-B FN expression might have a prognostic value in patients with HNSCC.

© 2004 Elsevier Ltd. All rights reserved.

## Introduction

Despite the important advances made in the management of head and neck squamous cell carcinoma (HNSCC), patients still have a poor prognosis with a 5-year disease-free survival (DFS) of about 50%.<sup>1</sup> The prognostic factors are mostly confined

\* Corresponding author. Tel.: +41 22 3728568; fax: +41 22 3724920.

E-mail address: [pmhawech1@yahoo.com](mailto:pmhawech1@yahoo.com) (P. Mhawech).

to the histopathologic and clinical parameters such as grade, stage, pattern of invasion, location, and lymph node metastasis.<sup>2–5</sup> Recently, numerous molecular markers such as cell cycle regulators, cell adhesion proteins, oncogenes and tumor suppressor-genes have been investigated in HNSCC. Some of these markers have shown promising results for future use.<sup>6–8</sup>

Fibronectin (FN) is a high-molecular mass adhesive glycoprotein; synthesized and secreted by numerous cell types, such as endothelial cells of neovasculature, stromal fibro/myofibroblasts, and tumor cells.<sup>9–12</sup> It is involved in numerous functions including cell adhesion, migration, homeostasis, wound healing and oncogenic transformation.<sup>13,14</sup> As shown by sequence analysis, FN is made up of three types of sequence homologies, types I, II, and III repeats, and has three sites of alternative splicing: ED-A (extra domain A), ED-B (extra domain B) and IIICS (type III homology connecting segment). Monoclonal antibodies against FN protein have been identified using immunohistochemistry (IHC); BC-1 and ED-A fibronectin, antibodies with a specific binding or recognition of the ED-B domain, and ED-A domain respectively and the glycosylated fibronectin antibodies such as FD-6 and 5C10, which define an oncofetal de novo O-linked glycosylation of the fibronectin molecular in the IIICS domain. However, studies have shown almost similar staining results using three different, 5C10, FD-6 and BC1, monoclonal antibodies.<sup>15,16</sup>

ED-B FN, also designated as oncofetal FN, due to its presence in fetal and tumor tissues but not in their normal counterparts.<sup>17</sup> Using IHC technique, numerous works have shown its expression in normal proliferative endometrium, chronic inflammatory diseases and ocular angiogenesis.<sup>18–20</sup> In addition, ED-B FN was detected in numerous tumors, including brain, breast, colon, and head and neck squamous cell carcinoma.<sup>16,18,21,22</sup> The intensity of FN staining in colorectal carcinoma has been associated with advanced local stage, liver metastasis and general prognosis.<sup>23</sup> In oral carcinoma, FN expression seemed to be associated with lymph node metastasis and mortality.<sup>24</sup>

Moreover, as a specific antibody (L19) with a high affinity to ED-B domain targeting the neovasculature in vivo has been identified, this antibody may have diagnostic and therapeutic values. It can be I-radio labeled (scFv) 2, so primary tumors as well as metastases may be detected, hence its potential use in imaging medicine.<sup>25</sup> On the other hand, when this antibody is labeled with a photosensitizer, animal models showed its high efficacy in selectively targeting tumor neovasculature, resulting in occlusion of blood vessels and thus cell

death.<sup>21</sup> These data on animal models showed a promising use of the L19 antibody for future clinical trials.

The aim of this study is first to determine the levels of ED-B FN expression in HNSCC and their relationship with the histological and clinical data and second to assess its utility in predicting outcome of patients with HNSCC after curative treatment with radiotherapy (RT) with or without chemotherapy.

## Materials and methods

### Patients population

A retrospective study covering 10 years (1992–2001) was conducted. Criteria for inclusion were patients with no prior treatment, histological diagnosis performed in our department and adequate material for analysis. Tumors with a nasopharyngeal origin were excluded from the study. Ninety-five patients were identified and selected for the present analysis. Patient and tumors characteristics are summarized in Table 1. After the initial diagnosis, patients were treated with radical RT with or without chemotherapy (see below). All patients were regularly followed up by the otolaryngologist, and the radio-oncologist. Treatment

**Table 1** Summary of patients and tumor characteristics that were included in the study

Median age (years) [range]	59 [35–85]
<i>Sex M:F</i>	77/18
<i>Tumor sublocation</i>	
Oral cavity	4
Oropharynx	58
Hypopharynx	21
Larynx	11
Paranasal Sinus	1
<i>TN classification and stages (UICC 1997)</i>	
T1-2	35
T3-4	60
N0	54
N+	41
Stage I–II	12
Stage III–IV	83
<i>Histology grading</i>	
Well differentiated (G1)	28
Moderately differentiated (G2)	42
Poorly differentiated (G3)	25

modalities and follow-up data were retrieved from the registry at the Division of Radiation Oncology. The median follow-up for the surviving patients was 44 months (range: 3–78).

## Treatment

All patients received the same accelerated RT schedule using concomitant boost technique. The latter has been described previously in detail.<sup>26</sup> The planned total dose was 69.9 Gy, delivered in 41 fractions over a period of 38 days. The basic course was given to a total dose of 50.4 Gy over 5.5 weeks. The boost to sites of initial macroscopic tumor involvement consisted of 19.5 Gy and was given as a second daily fraction, starting the last day of the second week of the basic treatment. According to our institutional policy,<sup>27</sup> five patients (6%) underwent a planned neck dissection prior to RT, either radical or modified radical while one patient had simple excisions of lymph node metastases. Otherwise, surgery was reserved for salvage of locoregional failures.

Chemotherapy was given to 27 patients (28%), usually for patients presenting with T3-4 or N2-3 tumors if their medical condition was judged good enough to tolerate multimodality treatment. All patients received one or more cycles of cisplatin  $\pm$  5-FU based chemotherapy concomitantly with RT.

## Immunohistochemistry

Tissue analyzed consisted of initial (pretreatment) biopsies. The original diagnosis was reviewed by two pathologists (PM, MA) and the histological grade was assessed using the WHO system. Immunohistochemistry (IHC) was performed on paraffin-embedded tissues. Tissue sections were deparaffinized with xylene and washed with ethanol. The method used was the alkaline phosphatase–antialkaline phosphatase (APAAP) method. For immunostaining enhancement, pretreatment by microwave oven in 0.01M citrate buffer (pH 6.0) at 98°C for 20min was done. Sections were incubated overnight at 4°C with the antimurine BC-1 antibody, recognizing the ED-B oncofetal FN isoform and diluted at 1:100. Immunostaining was performed by using the streptavidin–biotin–alkaline phosphatase complex staining kit (Biogenex, Basel, Switzerland) and fast red kit (Hamburg, Germany) as substrate to visualize the binding sites. Tissue sections from poorly differentiated squamous cell carcinoma of the head and neck were taken as positive controls. Sections from normal tissue such as laryngeal mucosae, skin, breast

and cervix, were used as negative controls. To test the specificity of the antibody, a normal goat serum was used in place of the primary antibody, resulting in a lack of detectable staining. Evaluation of the IHC was done by two pathologists (PM, MA) at a double head microscope who were neither aware of the original histological diagnosis nor of the clinical data. All the tissue on the slide was scanned for ED-B FN expression and cases were stratified in four categories negative, weak, medium and strong staining depending on the strength of intensity. Subsequently, cases were stratified in 2 groups; group 1 as negative (negative/weak expressions), group 2 as positive (medium/strong expressions).

## Statistical analysis

The Fisher's exact test was used to compare proportions and the two-tailed *T*-test to compare mean values of the different subgroups. The actuarial overall survival (OS) and disease-free survival (DFS) rates were calculated using the Kaplan–Meier method. For comparison between curves, the log-rank test was used. Multivariate analyses based on Cox proportional hazards standard model were used to identify the most significant factors related to outcomes. *p*-values of 0.05 or less were considered significant. All analysis was performed with the StatView V 5.0.1 software.

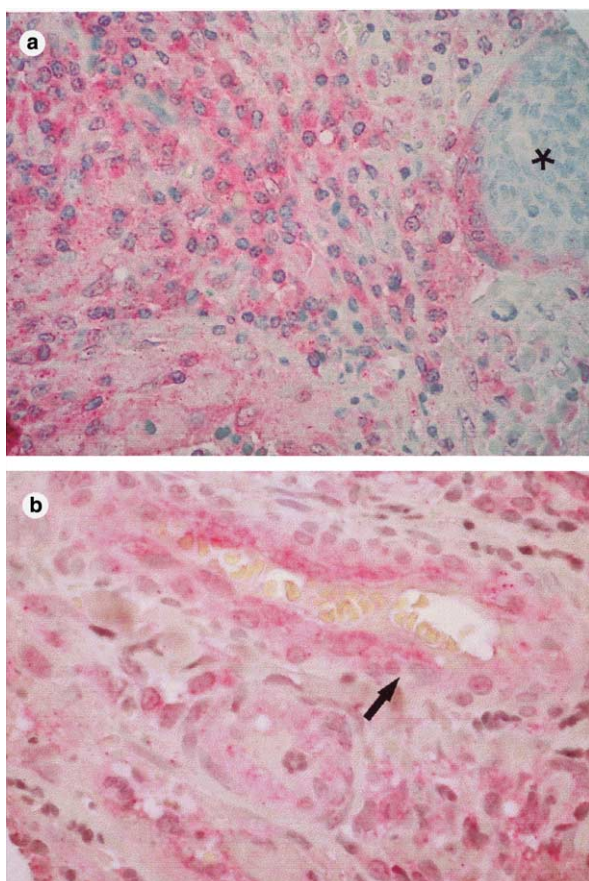
## Results

### Overall results

At last follow-up, 41 patients were alive, and 54 had died. Thirty-six patients presented with one or more events. Twenty-one patients presented with persistent or recurrent local disease, nine with regional disease (three regional only) and 13 with distant metastases (11 distant only). At 5 years, actuarial DFS was 54% (95% CI: 42–65%) and overall survival was 34% (95% CI: 23–46%).

### ED-B fibronectin and clinico-pathologic associations

In normal ED-B FN expression was totally absent in squamous mucosae, skin, cervix, and breast tissue sections. On ED-B FN evaluation, 44 cases were ED-B FN positive and 51 cases were negative (Figs. 1a and b, and 2). In positive cases, ED-B FN was expressed in the stroma, blood vessels and some



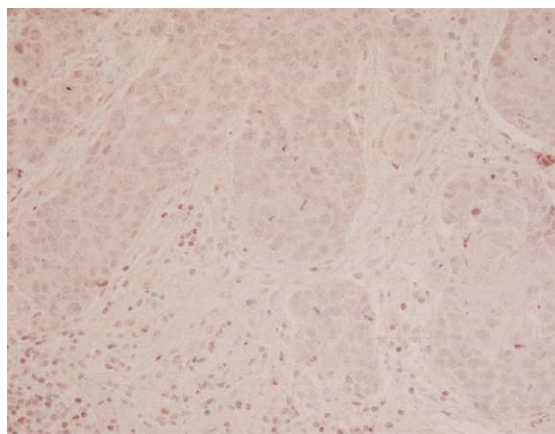
**Figure 1** An example of a case with strong positivity for ED-B FN where positive staining was found in the stroma, while the tumor cells are negative (asterisk) (a), also positive expression of ED-B FN was seen in endothelial cells of blood vessels (b).

tumor cells. FN was expressed in 32%, 45%, and 64% of G1, G2 and G3 cases respectively. Thus, there was a trend of significant association between ED-B FN expression and tumor grade ( $p = 0.06$ ).

When the ED-B FN expression was compared with various clinical features, there was no significant association between the FN expression and T stage ( $p = 0.99$ ) or lymph node status ( $p = 0.41$ ). However, there was a significant association between FN expression and tumor sublocation (oropharynx in 53%, hypopharynx in 47% and larynx in 9%,  $p = 0.02$ ).

### Univariate and multivariate analyses

In the univariate analysis, advanced T- ( $p = 0.034$ ) and N-categories ( $p = 0.016$ ) were associated with a significantly lower 5-year DFS, while the expression of FN was not (54% vs. 53%,  $p = 0.48$ ). However, the mean time to progression

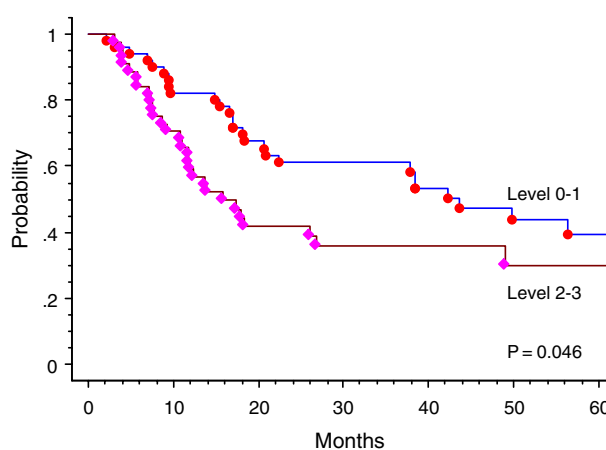


**Figure 2** An example of a carcinoma case with negative expression for ED-B FN.

was shorter in patients with tumor expressing FN (6 vs. 11 months,  $p = 0.13$ ).

For overall survival (OS), beside advanced T- ( $p = 0.014$ ) and N-categories ( $p = 0.04$ ), the expression of FN was significantly associated with lower 5-year survival rate (30% vs. 39%,  $p = 0.046$ ) (Fig. 3). Histologic grading (G1 vs. G2-3) and treatment category (with or without chemotherapy) did not correlate significantly with DFS nor with OS.

Factors significantly influencing OS in univariate analysis were included in the Cox model (except linked variables). In such a model, T-category ( $p = 0.004$ ) and N-category ( $p = 0.018$ ) retained their significance for OS while fibronectin expression was of borderline significance ( $p = 0.06$ ). The relative risks associated with these factors are listed in Table 2.



**Figure 3** Actuarial overall survival after therapy according to ED-B FN expression (log rank test of 0.046).

**Table 2** Cox proportional hazard model for overall survival according to ED-B FN

Variables	RR	95% CI	p-value
T-category: T1-2/T3-4	0.41	0.22–0.75	0.004
N-category: N0/N1-3	0.51	0.29–0.89	0.018
Fibronectin expression: level 0–1/2–3	0.6	0.34–1.03	0.06

RR: relative risk; CI: confidence interval.

## Discussion

Tumor stroma has been implicated to play a role in the invasive process of tumor by production of proteolytic enzyme and thus leading to the degradation of the extracellular matrix. In vitro studies showed the capability of ED-B FN to enhance adhesion and spreading of several cell types.<sup>28</sup> In vivo studies showed the expression of ED-B FN expression in numerous tumor types such as colon, breast and oral carcinomas, and brain tumors. Furthermore, the generation of a mouse monoclonal antibody, BC-1, which proved to be a reliable and an easy tool to handle, has encouraged many to use it in clinical studies.<sup>11,15,22</sup> Thus, the aim of our work is to determine the value of this protein in patients with HNSCC.

The first finding is the absence of ED-B FN staining in normal tissues such as normal laryngeal mucosae, skin, breast, endo and excocervical tissues; this is in agreement with the literature where no positive staining was seen.<sup>11,15,18,22</sup> In our study, positivity for ED-B FN was found in the cytoplasm of tumor cells, in the stroma and the endothelial cells of neovasculature. This finding is in agreement with the literature, showing that the source of ED-B FN are fibro/myofibroblasts, endothelial cells during angiogenesis and tumor cells themselves<sup>10,11,15,16,18</sup>. Furthermore, ED-B FN was present in 46% of cases, in accord with Lyons' study where positivity was seen in 43% of cases.<sup>24</sup>

As for the association of ED-B FN expression with the histological findings and the clinical data, among all parameters analyzed, including tumor grade, location, age, lymph node status, and UICC stage classification, only tumor location showed a significant association with ED-B FN expression. Therefore, tumors occurring in the larynx, which by far have better prognosis in comparison to those seen elsewhere, seemed to express ED-B FN to a lesser extent. This finding has not been described in earlier works. Furthermore, in those studies, tumor location was limited to the oral cavity,<sup>11,15</sup> or to the oropharynx,<sup>24</sup> or simply was not stated,<sup>22</sup> Second, ED-B FN expression did not show a signifi-

cant association to tumor grade. This finding is in accord with others.<sup>11,22,24</sup> In those studies, no association was seen between fibronectin expression and tumor grade. However, we must admit that, at the exception of Lyons' study, the number of cases in each of these works was very small. Furthermore, despite the series of 100 cases analyzed by Lyons et al, the result was somewhat bias by the tumor sampling where the majority of tumors were moderately differentiated tumors. In our study, even though we did not find a significant association between ED-B FN expression and tumor grade, a trend of association was present between these two parameters. Meaning, that if we increase the number of cases, a significant association between ED-B FN and tumor grade will be observed.

As for DFS and overall survival, even though the association between FN expression and DFS is not significant, our data showed that there is a tendency towards shorter time to progression in ED-B FN positive tumors (6 vs. 11 months). Thus, those patients with tumors strongly positive for the ED-B FN are expected to progress in a shorter time period than those patients with negative tumor expression. In univariate analysis, there is a significant association between ED-B FN expression by the tumor and overall survival, and a significant trend of association in multivariate analysis. Patients whose tumors express ED-B FN are expected to have shorter overall survival after RT/chemotherapy. We assume that more aggressive the tumor becomes and greater the production of ED-B FN is expected to occur. This finding is in agreement with a study by Lyons et al., who showed a relation between fibronectin intensity and mortality, where patients with intense tumor staining had higher rate of mortality than those with less intense staining. However, in his study Lyons did not perform a multivariate analysis to look whether fibronectin could have an independent prognostic value. In our hand, we found that patients with tumors expressing ED-B FN had a trend to a significant association for lower overall survival in multivariate analysis. Meaning and once again, that if we

increase the number of our cases, this finding will be of greater significance.

We must emphasize that the comparison between different studies is somewhat difficult, and subject to errors due to numerous factors. (1) Some studies used fresh tissue and others used formalin-fixed tissue, as each method has its advantage and disadvantage; e.g., in fresh tissue, we may face the problem of sampling error. In addition, the technique and the result interpretation are somehow difficult and subject to variations in our opinion. On the other hand, in formalin-fixed tissue, we have a good tumor sampling, tissue is easier to handle and manipulate and the interpretation of staining is much accurate. However, we might risk losing some staining intensity. (2) Some of those studies used monoclonal antibodies directed against the glycosylated fibronectin such as FD-6 and 5C10 and others against the ED-B fibronectin such as BC1. However, Mandel et al. showed that using three different monoclonal antibodies FD-6, 5C10, and ED-B FN, the staining results in all cases were almost similar.<sup>15</sup> Thus, despite the use of different antibodies, we can justify comparison among different studies. (3) Clinical data, location, grading and staging were not very clearly mentioned in the earlier studies, so comparison could not be made accurately. (4) Finally, the criteria used to define positivity for fibronectin expression was not homogenous in all the studies and most of the time was not stated.

In summary, ED-B FN expression in HNSCC might give us useful information on tumor behavior as it may identify patients at higher risk for shorter time to recurrence and for shorter or lower overall survival rate after therapy. However, these data have to be evaluated in a much larger more homogenous series of patients with HNSCC before further recommendations.

## Acknowledgements

We would like to thank F. Ludicke, MD for providing the antibody, Mr. Ludovic Metral for his technical skills, Mrs. Louise Hanggeli for her technical assistance and for Dr. Sophia Taylor for her reading the manuscript.

## References

- Landis SH, Murray T, Bolden S, Wingo PA. Cancer statistics. *CA Cancer J Clin* 1999;49:8–31.
- Wiernik G, Millard PR, Haybittle JL. The predictive value of histological classification into degrees of differentiation of squamous cell carcinoma of the larynx and hypopharynx compared with the survival of patients. *Histopathology* 1991;19:411–7.
- Crissman JD, Liu WY, Gluckman JL, Cummings G. Prognostic value of histopathologic parameters in squamous cell carcinoma of the oropharynx. *Cancer* 1984;54:2995–3001.
- DeStefani A, Magnano M, Bussi M, et al. Identification of clinical, biological and prognostic factors in recurring squamous cell carcinoma of the head and neck. *Acta Otorhinolaryngol Ital* 1997;17:219–24.
- Pera E, Moreno A, Galindo L. Prognostic factors in laryngeal cancer: a multifactorial study of 416 cases. *Cancer* 1986;58:928–34.
- Liu M, Lawson G, Delos M, et al. Prognostic value of cell proliferation markers, tumour suppressor proteins and cell adhesion molecules in primary squamous cell carcinoma of the larynx and hypopharynx. *Eur Arch Otorhinolaryngol* 2003;260:28–34.
- Khademi B, Shirazi FM, Vasei M, et al. The expression of p53, c-erbB-1 and c-erbB-2 molecules and their correlation with prognostic markers in patients with head and neck tumors. *Cancer Lett* 2002;184:223–30.
- Khan AJ, King BL, Smith BD, et al. Characterization of the HER-2/neu oncogene by immunohistochemical and fluorescence in situ hybridization analysis in oral and oropharyngeal squamous cell carcinoma. *Clin Cancer Res* 2002;8:540–8.
- Midulla M, Verma R, Pignatelli M, Ritter MA, Courtenay-Luck AJ, George AJ. Source of oncofetal ED-B-containing fibronectin: implications of production by both tumor and endothelial cells. *Cancer Res* 2000;60:164–9.
- Borsi L, Balsa E, Allemanni G, Zardi L. Differential expression of the fibronectin isoform containing the Ed-B oncofetal domain in normal human fibroblast cell lines originating from different tissues. *Exp Cell Res* 1992;199:98–105.
- Kosmehl H, Berndt A, Strassburger S, et al. Distribution of laminin and fibronectin isoforms in oral mucosa and oral squamous cell carcinoma. *Br J Cancer* 1999;81:1071–9.
- Pujuguet P, Hammann A, Moutet M, Samuel JL, Martin F, Martin M. Expression of fibronectin ED-A+ and ED-B+ isoforms by human and experimental colorectal cancer. Contribution of cancer cells and tumor-associated myofibroblasts. *Am J Pathol* 1996;148:579–92.
- Ruoslathi E. Fibronectin and its receptors. *Annu Rev Biochem* 1988;57:375–413.
- Hynes RO. Molecular biology of fibronectin. *Annu Rev Cell Biol* 1985;1:67–90.
- Mandel U, Gaggero B, Reibel J, Hamilton TM, Dabelsteen E, Clausen H. Oncofetal fibronectins in oral carcinomas: correlation of two different types. *APMIS* 1994;102:695–702.
- Kaczmarek J, Castellani P, Nicolo G, Spina B, Allemanni G, Zardi L. Distribution of oncofetal fibronectin isoforms in normal, hyperplastic and neoplastic human breast tissues. *Int J Cancer* 1994;59:11–6.
- Carnemolla B, Balza E, Siri A, et al. A tumor-associated fibronectin isoform generated by alternative splicing of messenger RNA precursors. *J Cell Biol* 1989;108:1139–48.
- Castellani P, Viale G, Dorcaratto A, et al. The fibronectin isoform containing the ED-B oncofetal domain: a marker of angiogenesis. *Int J Cancer* 1994;59:612–8.
- Berndt A, Borsi L, Luo X, Zardi L, Katenkamp D, Kosmehl H. Evidence of ED-B+ fibronectin synthesis in human tissues by non-radioactive RNA in situ hybridization. Investigations on carcinoma (oral squamous cell and breast carcinoma), chronic inflammation (rheumatoid synovitis) and

- fibromatosis (Morbus Dupuytren). *Histochem Cell Biol* 1998;**109**: 249–55.
20. Birchler MT, Milisavljevic D, Pfaltz M, et al. Expression of the extra domain B of fibronectin, a marker of angiogenesis, in head and neck tumors. *Laryngoscope* 2003;**113**: 1231–7.
  21. Nilsson F, Kosmehl H, Zardi L, Neri D. Targeted delivery of tissue factor to the ED-B domain of fibronectin, a marker of angiogenesis, mediates the infarction of solid tumors in mice. *Cancer Res* 2001;**61**:711–6.
  22. Birchler M, Viti F, Zardi L, Speiss B, Neri D. Selective targeting and photocoagulation of ocular angiogenesis mediated by a phage-derived human antibody fragment. *Nat Biotechnol* 1999;**17**:984–8.
  23. Infusa H, Nakamura M, et al. Localization of oncofetal and normal fibin in colon cancer. Correlation with histologic grade, liver metastasis and prognosis. *Cancer* 1995;**75**: 2802–8.
  24. Lyons AJ, Bateman AC, Spedding A, Primrose JN, Mandel U. Oncofetal fibronectin and oral squamous cell carcinoma. *Br J Oral Maxillofac Surg* 2001;**39**:471–7.
  25. Santimaria M, Moscatelli G, Viale GL, et al. Immunoscintigraphic detection of the ED-B domain of fibronectin, a marker of angiogenesis, in patients with cancer. *Clin Cancer Res* 2003;**9**:571–9.
  26. Allal AS, de Pree C, Dulguerov P, Bieri S, Maire D, Kurtz JM. Avoidance of treatment interruption: an unrecognized benefit of accelerated radiotherapy in oropharyngeal carcinomas. *Int J Radiat Oncol Biol Phys* 1999;**45**:41–5.
  27. Allal AS, Dulguerov P, Bieri S, Lehmann W, Kurtz JM. A conservation approach to pharyngeal carcinoma with advanced neck disease: optimizing neck management. *Head Neck* 1999;**21**:217–22.
  28. Chen W, Culp LA. Adhesion mediated by fibronectin's alternatively spliced Edb (EDIIIB) and its neighbouring type III repeats. *Exp Cell Res* 1996;**223**:9–19.

Available online at [www.sciencedirect.com](http://www.sciencedirect.com)

